

# Practical guide for the use of the Quantel Medical 577nm Multi-spot Laser: Supra Scan 577

**supra**  
scan



By Richard Rosen (New York, USA)  
& Bruno Lombroso - Marco Rispoli (Rome, Italy)



The latest generation of Quantel Medical Multi-spot Laser (Supra Scan 577) offers new technological features and treatment methods for improving retina laser therapy.

Quantel Medical Lasers give excellent clinical results using conventional laser photocoagulation at wavelengths which allow barely visible or below-threshold spots. They are optimized to allow shorter exposure times. They limit the heating of the retinal pigment epithelium and reduce the inflammatory response. OCT studies have confirmed that the laser photocoagulation effects are limited to the external retina, and there is no damage to retinal nerve fibres. Optimal long-term results are obtained with exposures that are barely visible or below the visible threshold. Immediate and late complications are significantly less than those resulting from conventional laser treatment.

While photocoagulation has been used in ophthalmology for more than 60 years, clinical and technical research continues, with the goal of developing better understanding of the effects of lasers on tissues and improving treatment strategies.

Following the introduction of xenon photocoagulators, used from the 1950s up through the mid-1970s, the field has continued to evolve and improve first with argon lasers, and krypton lasers, then solid state diode lasers (660nm & 810nm) and frequency-doubled YAG lasers (532nm) in the 1990's.

During the last three years the latest revolution in quality of delivery performance has taken place, with the introduction of a new 577nm solid state multi-spot laser: the Supra Scan 577.

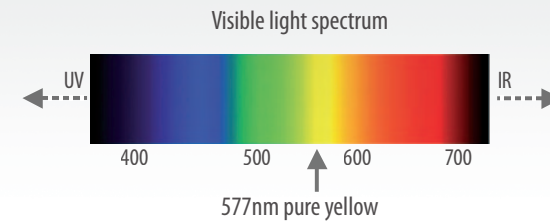


This newest generation laser offers specific technological features and treatment options designed to substantially improve the retina laser therapy:

- The more efficient yellow 577nm wavelength.
- The multi-spot delivery mode, which allows a single action of the pedal to send a burst of millisecond pulses in a preset pattern.
- The subthreshold micropulse mode, which generates customizable trains of microseconds pulses designed to minimize collateral injury to areas surrounding the target.

## | The 577nm yellow wavelength:

Identified as optimal in the ophthalmic clinical literature, the 577nm yellow wavelength is no newcomer to laser photocoagulation devices.



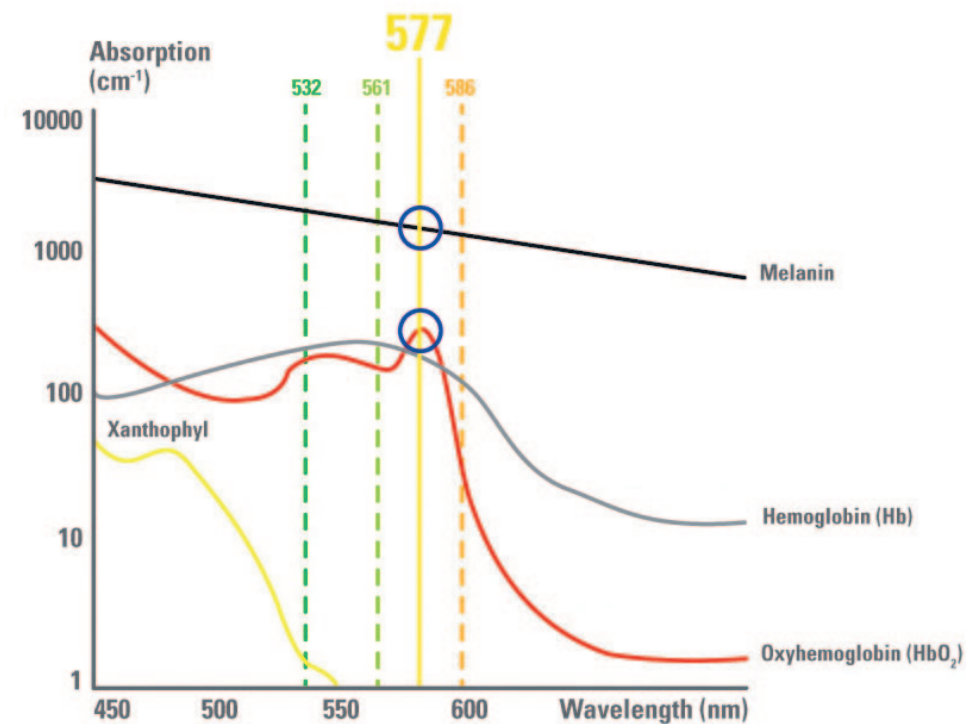
Previously available in krypton or dye lasers, it was a favored wavelength among retinal specialists.

Unavailable during an entire decade for technological reasons, the yellow wavelength is now available again with the improved efficiency and the reliability of the solid state technology.

The clinical absorption characteristics of the 577nm yellow wavelength have made it the wavelength of choice for retina treatments.

In retina photocoagulation treatment, the interplay of three chromophores is important:

- Melanin (in the RPE & choroid)
- Hemoglobin (in the blood and intravascular spaces)
- Xanthophylls (in the macula, must be avoided)



Compared to the commonly used 532nm green laser, the 577nm wavelength provides, better combined absorption by melanin and oxyhemoglobin, negligible xanthophyll absorption, low intraocular light scattering through partially-opacified media and high transmittance through cataracts.

In consequence this «ideal» wavelength allows improved treatment efficiency:

- Use of lower power settings
- More homogeneous treatment through cataracts
- Safer treatment adjacent to the macula

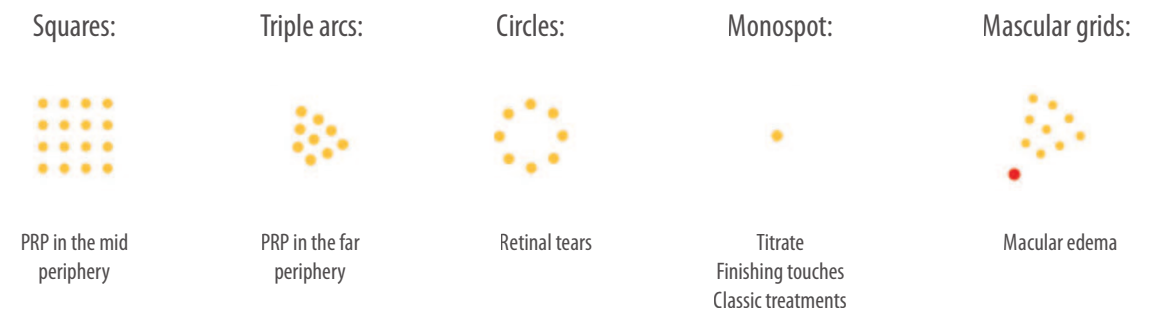
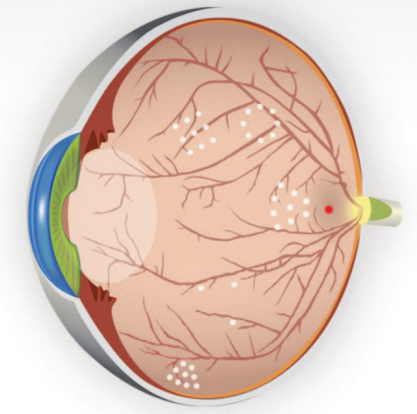
## | Semi-automated customized laser treatment method (multi-spot mode):

In the past the majority of retinal photocoagulation were achieved using continuous mode and single spots with pulse durations of 100ms to 200 ms.

These treatments, in particular panretinal photocoagulation, may be complicated by macular edema and may result in visual disturbances such as fan-shaped defects in the field of vision, concentric contraction of the peripheral visual field, and hemeralopia.. One of the most serious complications following classical posterior pole laser treatment is “atrophic creep” of the laser scar, resulting in loss of vision due to progressive subretinal fibrosis.

These adverse effects have been largely reduced through the use of the multi-spot mode.

The multi-spot mode employs short pulse durations of 10 to 20ms along with a variety of customizable grid patterns (squares / triple Arcs / circles / macular grid & single spot)

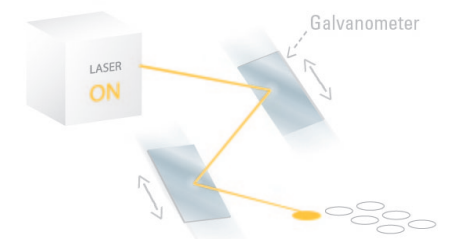


This semi-automated mode enables the surgeon to apply a preset grid of treatment spots with a single pedal action instead of having to manually place a treatment with successive re-aiming.

The grid pattern can be selected to fit the disorder being treated. Both the shape of the pattern and the number of spots can be preset.

Principle clinical advantages of the multi-spot mode include:

- Reduced heat diffusion through the retina and choroid
- Limited collateral damage to the surrounding tissue
- A more comfortable treatment experience for the patient
- Faster, more efficient treatment (full PRP in 2 sessions only)
- Shorter laser sessions

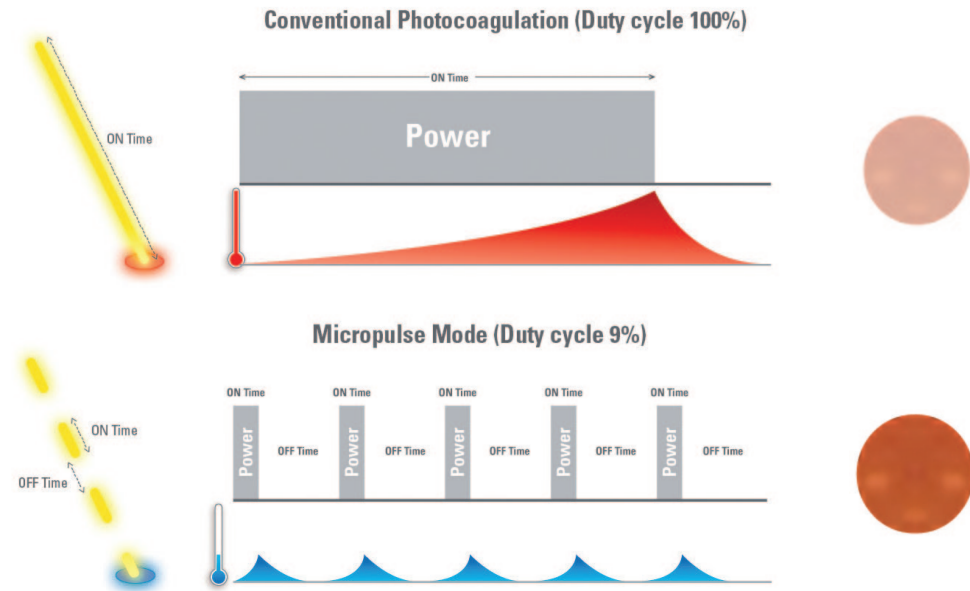




## Subthreshold laser treatment method (micropulse mode)

Subthreshold micropulse laser photocoagulation is a relatively new approach to laser therapy which is generating increasingly more interest among retinal physicians.

It consists of extremely short microsecond pulses of laser delivered with intervening periods with zero laser energy to limit the thermal effect of treatment in the targeted tissues.

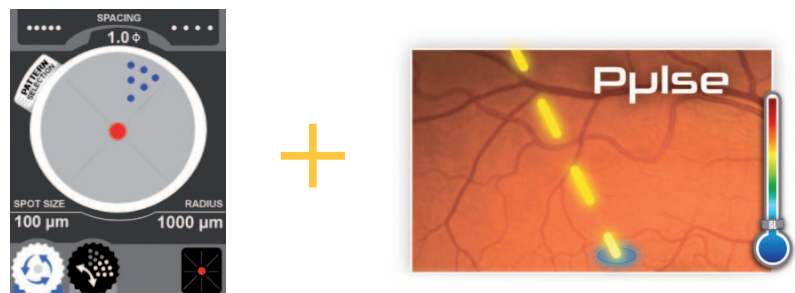


A number of ongoing clinical studies are currently investigating the ability of this tissue sparing treatment option to avoid scarring during treatment of macular pathologies such as diabetic macular edema and central serous retinopathy.

Preliminary results appear promising:

- Preservation of retinal tissue surrounding the treatment target
- A more gentle effect on the targeted area of the macula
- Absence of late scarring
- Ideal in combination with yellow laser for macular treatments
- Potential synergy when combined with intravitreal therapies for DME

Supra Scan 577 uniquely combines the multi-spot and the Micropulse laser emission modes for an easier and more selective treatment delivery:



## Differences between conventional 532nm lasers and 577nm multispot lasers for the operator

Operators accustomed to conventional single spot laser delivery systems will need to make certain adjustments when adapting to the use of the multi-spot system, but these are rapidly accomplished and result in greater operating comfort for both patient and physician.

The multiple aiming beam flashes rapidly.

The laser grid is not delivered simultaneously but forms rapidly in less than 0.5 sec for patterns consisting of 4 - 25 spots.

The laser power setting required depends on the degree of whitening desired, and of the amount edema present in the area of treatment.

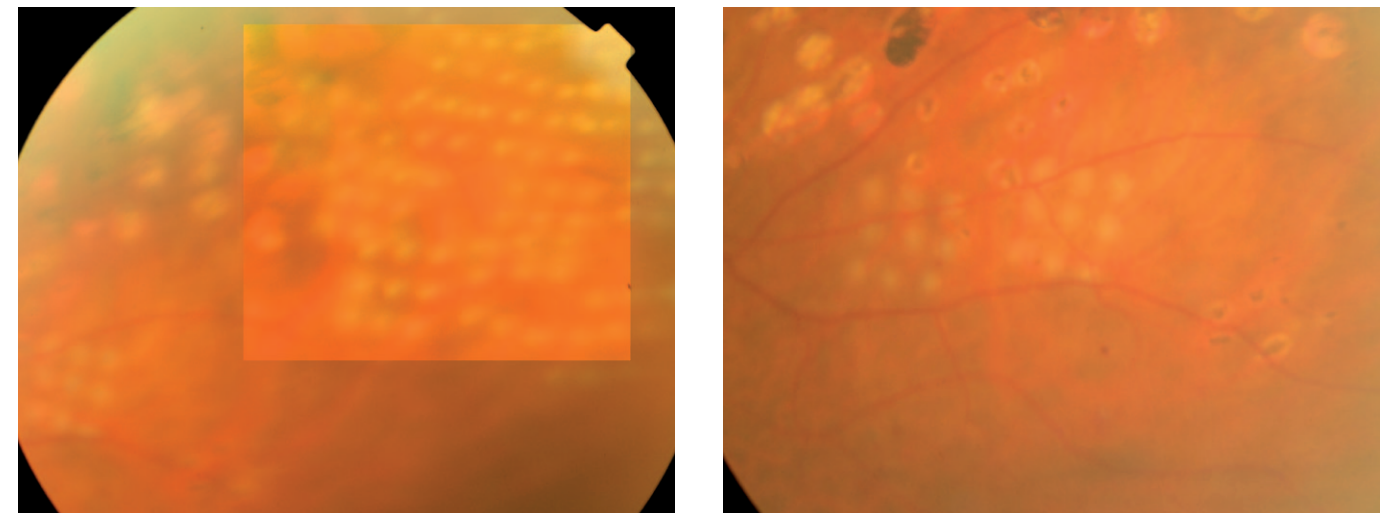
The power is titrated based upon the appearance of trial spots

The desired effect ranges from a barely perceptible graying to below-threshold bleaching for treatment in the posterior pole, and brighter whitening for the peripheral barriers around retinal tears.

Since the grid patterns are often large, it is difficult to achieve perfect focusing of all the spots with the laser's multiple aiming beam.

In cases of irregularly-shaped edema or non-homogeneous pigmentation of the fundus, the spots within the same grid may vary in appearance with intensities and colors ranging from pale pink to bright white.

With grids of more than 9 spots, the patient's saccadic eye movements may cause the pattern on the retina to appear somewhat irregular.



## | Advantages of the Supra Scan 577 Multi-spot Laser for the operator and the patient

The Supra Scan 577 Multi-spot Laser enables the operator to reduce treatment durations significantly by covering large areas of retina with single bursts of 4–25 spots.

Sessions typically last less than 10 minutes compared with the 15–20 minutes needed conventional laser delivery. Panretinal photocoagulation using this technique can often be applied in only two sessions, as opposed to the typical 4 sessions.

Both the precision and the efficiency of the treatment are enhanced.

Thanks to the 577nm wavelength and the multi-spot delivery mode:

The energy level required is lower than that used for conventional 532nm laser, resulting in less pain and a milder inflammatory response for the patient.

Treatment grids appear more regular, evenly spaced and of similar intensity.

The laser spots appear homogeneous (even in case of cataract)

The patterns are adjustable to fit each case according to the desired treatment regimen.

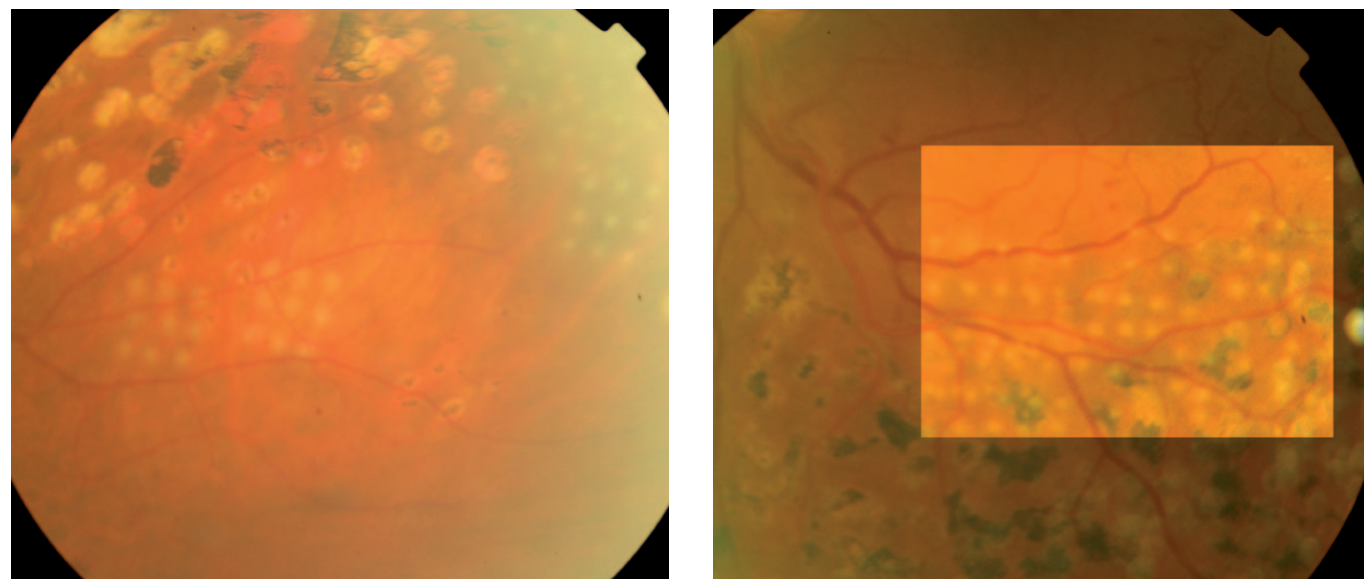
The rapidity of the delivery significantly reduces effects of patient movement. The longest bursts last half a second, but those consisting of nine spots are practically instantaneous and avoid the effect of most eye movements.

**In summary, the 577nm wavelength with multi-spot mode laser delivery offers both the ophthalmologist and the patient a great advance in comfort; the treatment is rapid, efficient and versatile.**

For the patient, the advantages include:

- Reduced pain,
- Reduced risk of retinal edema following the treatment
- Reduced light dazzle during treatment
- Shorter treatment sessions,
- More rapid vision recovery

Patients previously treated with conventional laser immediately recognize these advantages and show a strong preference for this new method.



## | Potential disadvantages and risks of the multi-spot laser delivery

Complications occur less frequently than with conventional laser therapy; specifically, the risk of post laser edema is reduced.

With treatments directed towards peripheral degenerations or tears, pattern delivery carries a slightly higher risk of laser burns to the pupillary border, resulting in pupillary deformation and permanent irregular mydriasis.

When larger patterns of 25 spots (5x5) are used, the longer burst time allows saccadic movements of the patient's eye to cause a deformation of the pattern on the retina, skewing the spacing of the spots. In more sensitive or more anxious patients it is preferable to use grids limited to 9 spots (3x3), which are shorter and avoid the effect patient movements during a burst.

Treatments using larger patterns (4x4 or 5x5) have difficulty avoiding retinal vessels that cross the impact field. When the laser involves a vessel wall, spasm may occur if the vessel is an artery or very occasionally hemorrhage if it is a vein. Such occurrences have not been reported to have any lasting effect with spasms disappearing within a few hours.



If larger 4x4 or 5x5 patterns are used in subjects who have previously undergone panretinal photocoagulation treatments, there is a risk that a scar area may be treated.

Even in these cases, no pain or other adverse effect has ever been observed. In conclusion, immediate or delayed complications are less frequent and less serious than with the conventional laser.

## | Precautions

It is most important to optimize the focus of the laser's multiple aiming beam on the retina; while this focusing is easily accomplished for "separate spots" in the range 50–100 microns, but is more difficult for larger multiple impact patterns.

For this reason, patterns larger than 4x4 are generally not recommended.

It is important to remember that the power of a multiple impact must be reduced when the area being treated moves from an edematous region of the retina to a normal one. It is also important to reduce the laser power appropriately as the spot diameter is reduced.

If the pattern is large, non-homogeneous grids may result, with some spots appearing sharply white and others appearing invisible, especially if there are areas of focal edema alternating with non-edematous retinal areas.

Regarding the posterior pole treatments, we recommend an application of the laser light at a safety distance of 300 to 400 microns from the foveal centre.



## | Indications for the Supra Scan 577 Multi-spot Laser

The indications of the multispot laser fall into three main groups:

- Treatment of retinal ischemia and proliferative retinopathies, especially proliferative diabetic retinopathy, but also other proliferative retinopathies and certain ischemic venous occlusions;
- Treatment of macular edema, especially diabetic retinopathies, but also venous branch occlusions;
- Prevention of retinal detachment (with treatment of rhegmatogenous peripheral retinal degeneration, especially lattice degeneration and the treatment of retinal tears).

The Multi-spot laser can be used in many other situations, alternating with the application of single spots, in particular in iridectomy and trabeculoplasty, as well as in minor applications such as pinguecula.

Laser treatment of subretinal neovascular membranes of the posterior pole is now restricted to some rare cases where the classical membrane is located more than 400 microns from the fovea. This therapy is difficult to perform and few ophthalmologists attempt it. Multispot treatment is not advised in such cases.

### Indications:

#### Vascular retinopathy

- Diabetic retinopathy: panretinal photocoagulation
- Non-diabetic proliferative retinopathy: panretinal photocoagulation
- Diabetic retinopathy: posterior pole edema
- Ischemic venous occlusions: panretinal photocoagulation
- Venous branch occlusions: focal treatment, partial macular grid

#### Prevention of retinal detachment

- Retinal tears
- Rhegmatogenous degeneration

#### Other applications

- Iridectomy
- Pinguecula

#### Contra-indications of multiple impact lasers

- Dense epiretinal membrane with traction
- Intense edema with serous detachment: first carry out anti-VEGF therapy.

## | Treatment techniques: general indications

### Patterns available:

It is currently possible to choose among four laser spot patterns: square, circular, arc and macular grid. The spot grid from each pulse is formed in a very short time.

The multiple spots are not produced simultaneously, but are formed in rapid succession, in less than 0.5 sec.

The spot diameters are smaller and the exposure time is appreciably shorter than in conventional laser treatment.

### Choice of pattern

Focal treatment:

Square patterns with few spots 2x2 or 3x3

Macular edema treatment:

Macular grid pattern

Panretinal treatment:

Square patterns 3x3, 4x4 or multiple arc

Barriers surrounding tears:

Multiple arc or circle pattern

For each pattern, we select:

The pattern shape


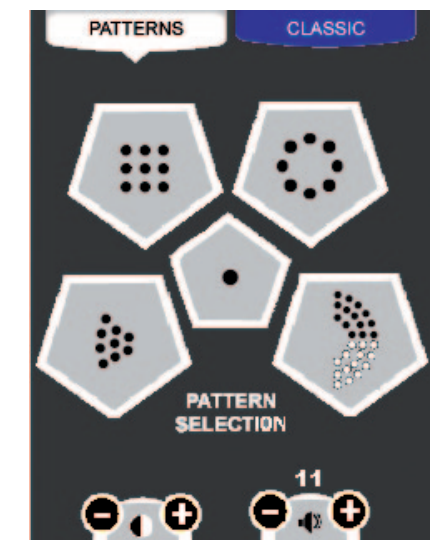
The number of spots per pattern

The diameter of each spot, 100 microns and above

The spacing of spots: This spacing is selected by multiplying the diameter of the spot by a coefficient indicated by the instrument. The spacing can range from 0 to twice the spot diameter. The reduced heat dispersion, permits more closely spaced burns.

### Characteristics of the patterns:

- Diameter of individual laser spots: 100–500 microns
- Spacing of laser spots according to their diameter (from 0 to 2 spots size)
- Wavelength: 577 nm
- Exposure time: 0.01–0.02 sec
- Maximum duration of the burst time (from 1 to 25 spots): 0.01–0.7 sec
- Power to obtain slight or below-threshold whitening
- Beam power: 60–600 mW
- Spot Size. Diameter (100–500 microns).



## | Laser exposure titration procedure

### Step 1: Lenses selection

In periphery:

- Wide field indirect lens like the Volk Superquad or Mainster PRP 165 lenses
- Goldman lens



In central area, lenses like the:

- Volk Area Centralis indirect lens or Mainster Focal / Grid Lens




### Step 2: Spot size selection

From 100µm to 500µm (50 - 100µm range available in classic mode only).

### Step 3: Power level selection

It is important to first test the reaction of the retina using single laser test spots.



Once the power which produces a slight or below-threshold whitening has been determined, the grid pattern is selected. We then select the number of spots in the grid: from 2x2 to 5x5 (4–25).

When we apply the treatment, the power, the shape and number of spots per pattern are adjusted as necessary, based upon the response of the retina during the session.

Typical number of patterns delivered per session: from 2 to 30–50.


## | Treatment of diabetic and other proliferative retinopathies

The main application of multi-spot lasers is panretinal photocoagulation, which is carried out very rapidly, painlessly for patients and with minimal glaucoma or dazzle. In the simplest cases the panretinal treatment is applied using a conventional laser with a total of about 2000 impacts, but in only two or three sessions. In progressive and more difficult cases, the therapy currently combines laser treatment with intravitreal injections of anti-angiogenic agents. These combined therapies are now adopted systematically; the intravitreal injections are very short-acting and have to be repeated every one to two months. In general, the laser treatment is carried out 7–21 days after the intravitreal injection. This combined therapy offers a better result than treatment with the laser alone.

A distinction can be made between two types of panretinal treatment: moderate, with about 2000 spots, and intense, with 3000–4000 spots.

In cases of rapidly progressing diabetic retinopathy in young subjects, the treatment must be very prompt and very intense, as also in cases of post-vitrectomy treatment requiring repeated, closely-spaced sessions.

In general, panretinal treatment begins with photocoagulation of the retinal periphery in the inferior and nasal sectors, and ends with application to the whole peripheral retina.





## When should panretinal photocoagulation be performed?

Proliferative diabetic retinopathy with high risk characteristics of optic disc neovascularization and other retinal neovascularization with vitreous hemorrhage  
Other proliferative retinopathies;  
Ischemic venous occlusion with an extension of more than 10 papillary diameters.

In cases of preproliferative diabetic retinopathy with an ischemic area larger than 10 papillary diameters, the operator decides whether to treat only the ischemic areas or to carry out a complete panretinal treatment.

## Parameter values recommended for panretinal patterns:

Pattern :	3x3, 4x4, 5x5 for a total of 9, 16, 25 spots per burst.
Spot size :	100–300 microns
Exposure time :	0.01–0.02 sec
Effect desired :	retinal whitening
Power :	100–600 mW
Spot spacing :	from 0.5 to 2 spot diameter (0.5 usually recommended)

To obtain 400 spots, 25–40 bursts of impacts (patterns) have to be applied, with a total duration of 7–10 minutes.



## Treatment of edema of the posterior pole for diabetic retinopathies and venous occlusions

It is important to study retinal edema accurately by OCT and fluorescein angiography before carrying out laser treatment. This makes it possible to assess the extent and topography of the edema, and localise the presence of epiretinal membranes. If the edema is partly due to traction of the membranes on the retina, the laser treatment, even after injection of anti-angiogenic agents, is not very useful and it is preferable to consider immediate surgery followed by an intravitreal injection of anti-angiogenic drugs, and then a multispot laser treatment two weeks later.

Laser photocoagulation is currently the gold standard for the treatment of diabetic macular edema, and the results obtained are used to compare the efficacy of the other treatments. For more than 30 years, large-scale trials have shown vision improvement after laser therapy. Gradual improvement continues in time because laser photocoagulation also has a delayed effect.

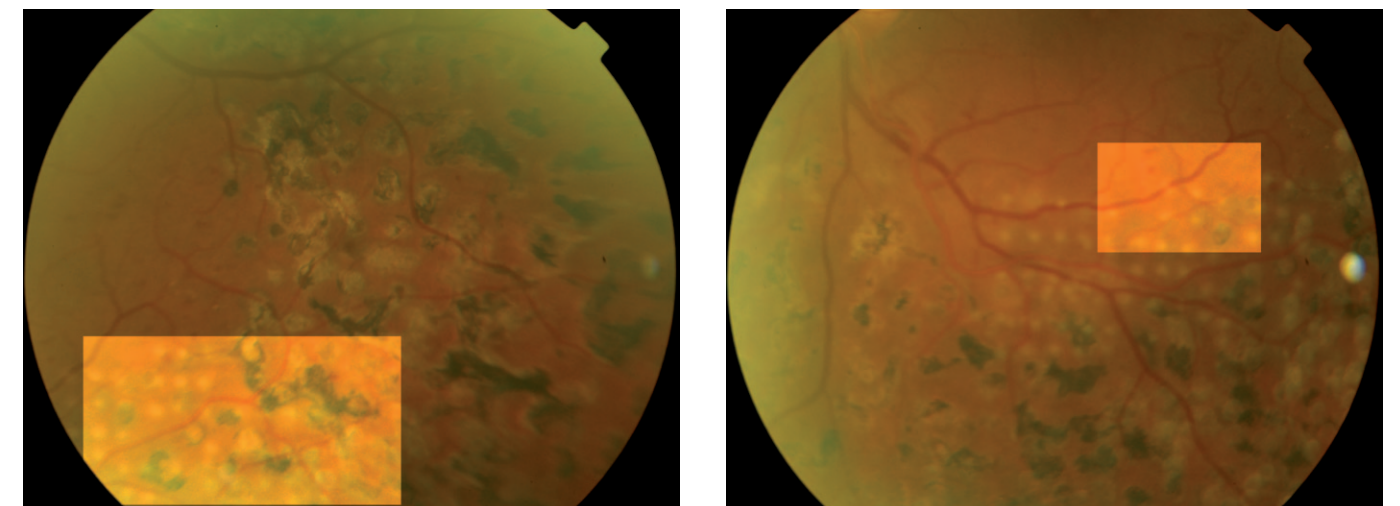
Currently, the tendency is to combine the laser treatment with intravitreal injections of anti-angiogenic agents.

Even in cases of branch venous occlusion, the results of recent clinical research argue for associating laser treatment with intravitreal injections of anti-angiogenic drugs.

In cases of focal edema, the area of thickening and intraretinal microvascular injury at the center of the circinate lesions are treated with a square 2x2 or 3x3 pattern.

In cases of diffuse edema, the treatment of the posterior pole makes it possible to apply a very regular macular pattern using the “macular treatment” pattern. This is performed by rapidly moving an impact beam with set sectors around a fixed point in such a way as to keep a radius of 1000 microns of free retina around the fovea. The treatment can be general or be applied on only one or two sectors. The laser power is titrated to produce minimal bleaching or even fall below the visible threshold. This technique can also be applied to cases of retinal edema secondary to venous occlusion.

In cases of diabetic retinopathy or more serious venous occlusion, with cystoid edema and numerous pseudo-cysts, we sometimes observe major retinal thickening of 400–800 microns. In such cases, surgery is indicated, associated with an injection of anti-angiogenic agents, followed by laser treatment for edema reduction, in general 10–20 days after the injection. The anti-angiogenic drugs give results that last only two or three months if the laser treatment is not performed in conjunction in a timely manner.






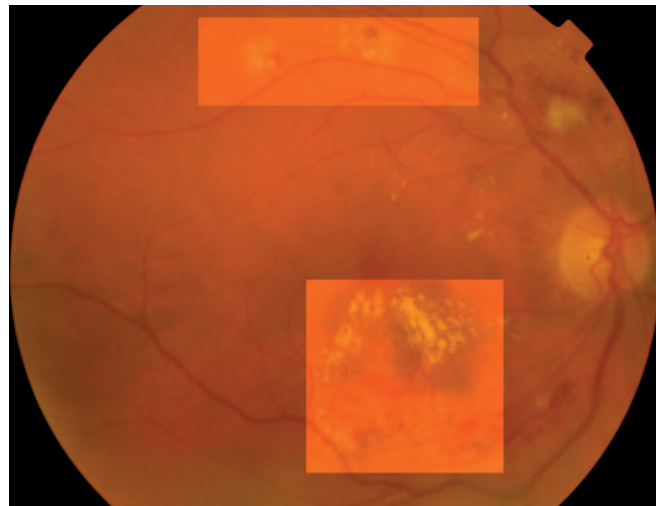
## Contraindications to use of multi-spot lasers for retinal edema

Dense epiretinal membrane with traction  
Intense edema with serous detachment: first carry out anti-VEGF therapy.

## Parameter values recommended for the treatment of focal macular edema: focal photocoagulation

Pattern :	grid array, 2x2 or 3x3
Spot size :	100–200 microns
Exposure time :	0.01–0.02 sec
Effect desired :	barely perceptible or below-threshold whitening
Power (strongly depends on degree of edema) :	50–120 mW
Spot spacing :	at least one spot diameter apart

To obtain 400 spots, 25–40 bursts of impacts (patterns) have to be applied, with a total duration of 7–10 minutes.



## Parameter values recommended for the treatment of diffuse macular edema: grid photocoagulation

Pattern :	sectors centered on fovea
Spot size :	100–200 microns
Exposure time :	0.01–0.02 sec
Effect desired :	barely perceptible or below-threshold whitening
Power (strongly depends on degree of edema) :	50–120 mW
Spot spacing :	at least one spot diameter apart

To obtain 80 spots, 5–6 bursts of impacts (patterns) are needed minutes.

Treatment of diffuse macular edema: grid photocoagulation

## Treatment of retinal tears and prevention of retinal detachment

For the past forty years laser treatment has remained one of the most used methods for the prophylaxis of retinal detachment.

The use of laser treatment in the prevention of retinal detachment is possible if two conditions are met: (i) retinal lesions with predisposition for detachment and (ii) risk factors.

The retinal lesions that may give rise to retinal detachment are, in order of seriousness: retinal tears, peripheral lattice retinal degeneration, acquired retinoschisis, and white-without-pressure and snail-track retinal degeneration.

The risk factors are, in order of seriousness: recent vitreous detachment with visual symptoms (photopsia, new onset floaters), severe myopia, retinal detachment in the contralateral eye and family history of retinal detachment.

In general, a barrier is made around the lesion. This barrier can be made with a circular or arc pattern. A triple line of near-contiguous laser spots should to be applied. For the scar to be robust, the impacts have to be 500 microns in size, white and intense. The scar is pigmented and resistant after 20–30 days.

## Retinal lesions that may cause detachment

### Retinal tears

### Peripheral retinal degeneration :

- Lattice
- Acquired retinoschisis
- White-without-pressure
- Perivascular vitreo-retinal adhesions
- Snail-track.

Some peripheral retinal degenerative lesions present no real risk of retinal detachment. It is up to the operator to decide whether the risk factors are serious enough to justify preventive laser treatment.

- Congenital retinoschisis
- Pavingstone degeneration
- Snowflake degeneration although in certain cases the similarity to snail-track degeneration suggests some risk, especially if associated with other lesions;
- Reticular equatorial degeneration
- Equatorial drusen
- Microcystic degeneration

Small retinal holes on a healthy retina carry a minimal risk of contributing to retinal detachment, especially when these are degenerative and asymptomatic holes without evidence of associated vitreous traction.

### Important risk factors:

- Recent detachment of the vitreous body with visual symptoms (photopsia, new onset of floaters)
- Degenerative myopia
- Surgery for cataract and aphakia-pseudophakia
- Retinal detachment of contralateral eye
- Family history of retinal detachment.

### Parameter values recommended for treatment of retinal tears or peripheral dystrophy with surrounding laser barriers

Pattern :	linear, circular or arc, 3 or 5 spots
Spot size :	100–500 microns
Exposure time :	0.01–0.02 sec
Effect desired :	well-marked retinal whitening
Power (strongly depends on degree of edema) :	100–300 mW
Spot spacing :	at least one spot diameter apart

To obtain 200 spots, 10-15 bursts of spots (patterns) are needed

## I Conclusions

The use of the Supra Scan 577 Multi-spot laser allows reduction of both pain and duration of treatment. The precision and efficacy of the treatment are improved. The impact generates a smaller scar and a milder inflammatory response. The laser spots are much more regular, evenly spaced and homogeneous. The patterns can be customized. The bursts are practically instantaneous and short enough to avoid eye movements during bursts.

### Advantages for the ophthalmologist and the patient:

For the patient, there is less retinal edema after treatment, less dazzle and above all less or no pain and a shorter treatment duration.  
For the ophthalmologist the multiple impact laser offers greater comfort in use; the treatment is rapid, efficient and versatile.

The Supra Scan 577 Multispot Laser is thus a modern laser treatment device that is simple, practical, semi-automated and customizable.

It uniquely combines three of the most clinically sought-after components in a retina laser; the 577nm yellow wavelength, the multi-spot delivery mode and the Micropulse tissue-sparing promising mode.

In the near future further technological advances will allow retinal photocoagulation to become more automated, based on diagnostic assessment by angiograms and OCT, and utilizing computer assistance.

### Contacts:

Richard Rosen  
rrosen@nyee.edu

Bruno Lumbroso  
bruno.lumbroso@gmail.com







[www.quantel-medical.com](http://www.quantel-medical.com)

**Headquarters**

Quantel Medical  
11, rue du Bois Joli - CS40015  
63808 Cournon d'Auvergne - FRANCE  
Tel: +33 (0)4 73 745 745  
Fax: +33 (0)4 73 745 700  
E-mail: [contact@quantel-medical.fr](mailto:contact@quantel-medical.fr)

**North America**

Quantel USA  
601 Haggerty Lane  
Bozeman, MT 59715 – USA  
Tel: +1 877 782 6835  
Fax: +1 406 522 2005  
E-mail: [info@quantelmedical.com](mailto:info@quantelmedical.com)

**Representative Offices**

Thailand, Chiang Mai  
Brazil, Rio De Janeiro